

**PATIENT**

Nala Mojica

**SPECIES**

Canine

**BREED**

Chihuahua

**SEX**

Female Spayed

**AGE**

11 years

**WEIGHT**

10.6lbs

**INTERPRETED BY**

Maggie Machen Lamy,  
DVM, DACVIM  
(Cardiology)

**IMAGING PERFORMED BY**

Kuzimski, DVM

**HOSPITAL NAME**

Animal Emergency  
Hospital Deland

**REFERRING VET**

Dr. Kuzimski

**INVOICE**

47359

**DATE**

3/29/26

**PRESENTING CLINICAL SIGNS**

History: Grade 5/6 heart murmur. Increase RR and RE. BP: 151mmHg.

**ELECTROCARDIOGRAPHIC FINDINGS** \*Note: Single lead ECGs are evaluated as a rhythm strip. Morphology/MEA cannot be definitively commented on.

A single lead ECG is available; 25mm/s, 10mm/mV. The average heart rate is 160bpm. The rhythm is sinus in origin, with a p for every QRS complex and vice versa. The P and QRS morphologies are positive. Isolated APCs. No VPCs, pauses or other dysrhythmias observed. ECG diagnosis: Normal sinus rhythm with isolated APCs.

**ECHOCARDIOGRAM FINDINGS**

2D, m-mode and color flow imaging are available. Diffuse thickening of mitral valve leaflets (anterior > posterior) with prolapse into the left atrial lumen. Severe eccentric mitral regurgitation with severe left atrial dilation. Significant LV dilation with hyperdynamic myocardial function. The tricuspid valve appears mildly thickened with septal prolapse and trace tricuspid regurgitation. Mild right atrial and ventricular dilation. The pulmonic and aortic valves are normal in morphology and mobility. No pericardial or pleural effusion noted. No cardiac tumors observed.

**CARDIAC CHART**

CANINE CARDIAC PARAMETERS	MR VMAX (m/s)	TR VMAX (m/s)	LA/AO (Boon method)	LA/AO (Heart Base; Swe)	FS (%)	EF (%)	EPSS (cm)
<b>NORMAL PARAMETER</b>	4.5-5.5	<2.7	1.3	<1.6	28-40	40-100	<0.6
<b>PATIENT</b>	NM	NM	NM	2.2	48	90	NM
CANINE CARDIAC PARAMETERS	HR (BPM)	AV VMAX (m/s)	PV MAX (m/s)	BODY WEIGHT (kg)	LA 2D short axis Base view (cm)	LVIDd Avg; 2D and m-mode short axis (cm)	LVIDs Avg; 2D and m-mode short axis (cm)
<b>NORMAL PARAMETER</b>	50-100	0.7-1.7	0.7-1.6	BELOW	BELOW	BELOW	BELOW
<b>PATIENT</b>	NM	NM	NM	4.8	2.5	3.3	1.6
*Normal chamber parameters expressed as a mean value (SD)				3	1.27 (5.3)	2.46 (2.46)	1.36 (5.5)
<b>BODY WEIGHT DEPENDENT PARAMETERS</b>				5	1.40 (4.5)	2.74 (5.2)	1.60 (4.7)
*Note: All measurements based upon multi-modal images and methods. An average value is reported.				10	1.50 (3.8)	3.27 (3.5)	2.06 (3.1)
				15	1.83 (2.0)	3.71 (2.4)	2.43 (2.1)
				20	2.02 (1.9)	4.14 (2.2)	2.80 (2.0)
				25	2.18 (2.4)	4.48 (2.9)	3.10 (2.5)
				30	2.33 (3.3)	4.83 (3.9)	3.39 (3.4)
				35	2.48 (4.3)	5.17 (5.0)	3.69 (4.5)
				40	2.62 (5.2)	5.48 (6.1)	3.96 (5.4)
				50	2.88 (7.1)	6.07 (8.3)	4.46 (7.4)

**INTERPRETATION OF THE FINDINGS & FURTHER RECOMMENDATIONS**

The cause of the murmur is chronic degenerative valve disease causing severe mitral and trace tricuspid regurgitation. Severe left atrial enlargement indicates the risk for spontaneous



## PATIENT

Nala Mojica

## SPECIES

Canine

## BREED

Chihuahua

## SEX

Female Spayed

## AGE

11 years

## WEIGHT

10.6lbs

## INTERPRETED BY

Maggie Machen Lamy,  
DVM, DACVIM  
(Cardiology)

## IMAGING PERFORMED BY

Kuzimski, DVM

## HOSPITAL NAME

Animal Emergency  
Hospital Deland

## REFERRING VET

Dr. Kuzimski

## INVOICE

47359

## DATE

3/29/26

congestive heart failure is elevated. Early pulmonary hypertension is not ruled out without adequate spectral doppler and may certainly be present as well. No additional issues are seen.

The ECG is largely normal with isolated APCs. These are not surprising in a dog with severe structural disease in crisis. No treatment is indicated based upon what is seen here.

The described respiratory signs are likely multi-factorial in origin, including possible concurrent airway disease and/or early CHF given the severity of disease. Screening chest radiographs are recommended with any change in symptom; however, given the symptoms and echo findings, **full lifelong cardiac support is recommended as below** including Lasix therapy. Depending on clinical response to the medications, cough suppression may also be useful. **Monitoring of sleeping breathing rates in the future will be paramount to determine the origin of any future cough.** The average survival of canine patients with active pulmonary edema is 8-9 months on medications; however, they generally are able to maintain a good quality of life for that period. Patient will always be at risk for recurrent CHF, development of arrhythmias/LA tear, syncope and/or sudden death in the future. Monitoring of renal values is recommended lifelong.

Omega fatty acid supplementation and mild salt restriction may also be of some long-term benefit. Monitor for development of a worsening cough, labored breathing, exercise intolerance or collapse episodes.

Elective anesthesia is not advised, as there is high risk for complication.

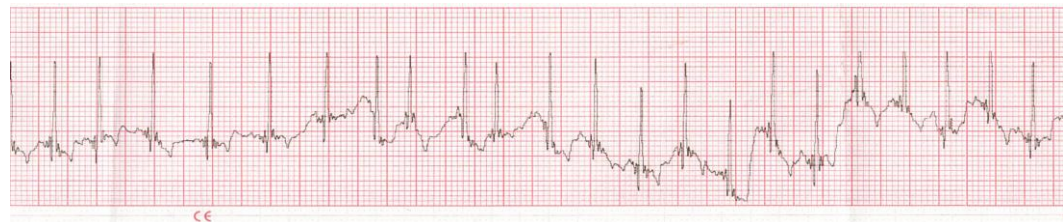
## PLAN

Screening CXR recommended. Administer Pimobendan 0.3mg/kg PO q12h. Administer low dose furosemide/Lasix 1 mg/kg PO q12h. Administer spironolactone 1-2mg/kg PO q12h. Consider hydrocodone with homatropine (0.2-0.4mg/kg PO up to q4-6 hours PRN) if cough persists despite normal SRRs.

A renal panel and BP are recommended in 10-14 days, then every 3-4 months on diuretics to ensure tolerance of medications. If doing well at that time and BP >130mmHg, institute ACEI 0.5mg/kg PO q12h.

A recheck echocardiogram and ECG are recommended in 6 months to screen for progression, sooner if clinical signs arise/persist.

## IMAGES



CE



## PATIENT

Nala Mojica

## SPECIES

Canine

## BREED

Chihuahua

## SEX

Female Spayed

## AGE

11 years

## WEIGHT

10.6lbs

## INTERPRETED BY

Maggie Machen Lamy,  
DVM, DACVIM  
(Cardiology)

## IMAGING PERFORMED BY

Kuzimski, DVM

## HOSPITAL NAME

Animal Emergency  
Hospital Deland

## REFERRING VET

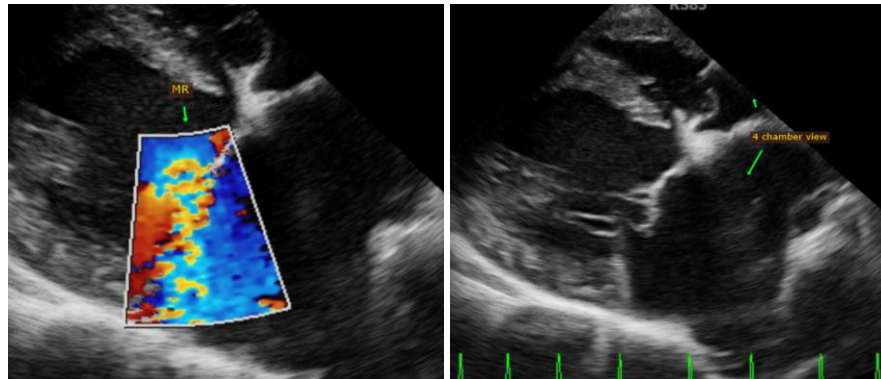
Dr. Kuzimski

## INVOICE

47359

## DATE

3/29/26



The information and recommendations provided are based on the images presented by the referring veterinarian. No evaluation can be communicated regarding pathology that was not visible in the image/video clips provided.

Thank you for this referral. This report was generated using transcription software, and minor dictation errors may be present. If the clinical or image interpretation does not parallel your findings or if I can be of any further assistance, please contact me.

**Maggie Machen Lamy, DVM**

**Diplomate of the American College of Veterinary Internal Medicine (Cardiology)**

info@sonopath.com